

Histomorphological Effects of *DaucursCarota* Extract on Dispirin Induced Kidney Damage in Albino Rats

Ikem Amarachi Promise, Okolie Nnamemeka and Nnodim Johnkennedy*

Department of Medical Laboratory Science, Faculty of Health Science, Imo State University, Owerri, Nigeria

ABSTRACT

This study was carried out to investigate the protective effect of extract against dispirin induced renal toxicity in albino rats. The histological effect of consumption of *Daucurscarota* root extract on the kidney of albino rats was carried out. The albino rats were divided into five groups. Each group consists of 5 albino rats. Group A serves as control while group B, C, D and E received dispirin 80 mg/kg/day, 50mg, 100mg and 200mg/kg body weight per day of *Daucurscarota* extract respectively for a period of 28 days. Serum samples from each rat were subjected to biochemical analysis for kidney functions, while kidney biopsies were also investigated by histological examination. Dispirin significantly increased serum creatinine, urea, ($p < 0.05$). Moreover, dispirin induced significant histological and ultrastructural alterations in the renal tissues of the rats. The exposure to *Daucurscarota* extract did attenuate the dispirin-induced toxicity in renal tissues. These results suggest that *Daucurscarota* extracts have significant protective role against dispirin-induced renal toxicity.

Keywords: *Histomorphological, Effects, DaucursCarota, Extract, Dispirin, Kidney Damage, Albino Rats*

Introduction

Ikem, A.P., Okolie, N. and Nnodim, J. (2022). Histomorphological Effects of *DaucursCarota* Extract on Dispirin Induced Kidney Damage in Albino Rats. *Madonna University Journal of Medicine and Health Sciences*.2(1):204-217

The use of plants and plant extracts as trado-medical relief has been in existence for ages. This practice has been encouraged in recent times due to the less frequent side effects when compared with orthodox medicine. There has been growing interest in the investigation of the alternative route for the substitution of synthetic chemicals side effects, which are always in question (Wang *et al.*, 2010). Irrespective of the successes achieved using technology, the intuitive individuals across different geographical terrain especially developing countries still continue to use herbs for the treatment of certain ailments, either as a result of poverty or the efficacy of the herbal products. The use of herbal medicines and phytonutrients or nutraceuticals continues to expand rapidly across the world with many people now resorting to these products for treatment of various health challenges in different national healthcare settings. This past decade has obviously witnessed a tremendous surge in acceptance and public interest in natural therapies both in developing and developed countries, with these herbal remedies being available not only in drug stores, but now also in food stores and supermarkets (Mimura *et al.*, 2008).

As the global use of herbal medicinal products continues to grow and many more new products are introduced into the market, public health issues, and concerns surrounding their safety are also increasingly recognized. Although some herbal medicines have promising potential and are widely used, many of them remain untested and their use also not monitored. This makes knowledge of their potential adverse effects very limited and identification of the safest and most effective therapies as well as the promotion of their rational use more difficult. *Daucurscarota* is popularly known as carrot. Carrots are eaten raw in salads; cooked in soups, stir-fries, and casseroles; served alone as a side vegetable; and processed to make baby foods. Carrot is frequently used as a colourful garnish, often grated, sometimes sculpted into decorative flower-like shapes. Carrot juice is popular as a healthy drink, both alone or mixed with other vegetable and fruit juices. Carrots are used in sweet dishes such as carrot cake and in Asia often used in jams and syrups. Carrots are a source of the natural food dye carotene. Carrot fruit oil has been used for flavouring liqueurs and as an ingredient in cosmetics (Daniel, 2017).

Ikem, A.P., Okolie, N. and Nnodim, J. (2022). Histomorphological Effects of *DaucursCarota* Extract on Dispirin Induced Kidney Damage in Albino Rats. *Madonna University Journal of Medicine and Health Sciences*.2(1):204-217

Essentially, herbal remedies consist of portions of plants or unpurified plant extracts containing several constituents which are often generally believed to work together synergistically (Gabriella and Hans, 2003). *DaucursCarota* are grown in the Northern Nigeria and used widely in Southern Nigerian states for various purposes such as treatment of infections and several ailments but its histopathological and effects on body tissues have been overlooked because of the properties and uses of these plants (Clark and Wilson, 2003; Branski *et al.*, 2012). Hence, this study is centered on the histopathological effects of *DaucursCarota* on dispirin induced kidney damages in Wistar rats.

Materials and methods

Animals

The twenty eight albino rats were bought from the animal house of College of Medicine and Health Science, Imo State University, Owerri Imo State. Albino rats of both sexes weighed between 180g to 200g maintaining under standard laboratory were used for the experiment. They were fed with grower mash bought from Farm Enterprises Nigeria Distributors of animal feeds, no 68 Mbaise Road Owerri.

The present study was experimental, with the use of an animal model. The animal study was carried out in compliance with the policies outlined in the 'Guide for the Care and Use of Laboratory Animals.

Plant Collection and Authentication

Ikem, A.P., Okolie, N. and Nnodim, J. (2022). Histomorphological Effects of *DaucursCarota* Extract on Dispirin Induced Kidney Damage in Albino Rats. *Madonna University Journal of Medicine and Health Sciences*.2(1):204-217

The root of *Daucuscarota* was obtained at Ekeonunwa Market Owerri. It was identified by the Head Department of Plant Biology and Biotechnology, Faculty of Science, Imo State University Owerri, Nigeria.

Extract Preparation; The roots of *Daucuscarota* were kept at room temperature (29°C) in the Laboratory and pulverized into uniform fine powdered particle and sieved.. The dried down extract was reconstituted in distilled water for animal oral treatment by using 2g of the concentrated plant filtrate, dissolved in 20ml of distilled water to give a concentration of 100mg/ml

Study Design

Five groups of five male albino rats were used in the experiment. Each group was treated and fed as follows for four weeks:

Group 1: served as the normal control and received deionized water; Group 2: served as toxic control and received Dispirin solution; Group 3: Dispirin solution plus 50 mg/kg body weight *Daucuscarota*; Group 4: Dispirin solution plus 100 mg/kg body weight. *Daucuscarota*; Group 5: Dispirin solution plus 200 mg/kg body weight *Daucuscarota*.

The dose of the *Daucuscarota* extract used was administered by oral compulsion. The body weights were measured before commencement of the study and 28 days after administration.

On the 28th day, the rats were fasted overnight, weighed, and sacrificed under ether anesthesia on the 29th day. The blood samples were collected by cardiac puncture and kept at temperature of 4°C for 6 hours. The blood samples were then centrifuged at 3000 rpm for 15 minutes and stored

Ikem, A.P., Okolie, N. and Nnodim, J. (2022). Histomorphological Effects of DaucursCarota Extract on Dispirin Induced Kidney Damage in Albino Rats. Madonna University Journal of Medicine and Health Sciences.2(1):204-217

properly for further analysis. The left kidney was stored in 10% formaldehyde and processed for histological examination.

Biochemical analysis

Determination of serum creatinine by Jaffe's Method and serum

urea by enzyme methods (Rashid *et al.*, 2005).

Histology

For light microscopy examination, the formalin fixed tissues (kidney) were dehydrated through ascending grades of alcohol, cleared in three changes of xylene, and were embedded in paraffin. Serial sections, each of 4-micron thickness, were cut and stained with H and E as per standard protocol. Stained sections were morphologically evaluated, and the pictures of the slides were taken for comparison.

Tissue processing;

At the termination of the experimental study, all the animals (treated and untreated) were sacrificed by (chloroform) anaesthetization. The visceral organs of interest (kidney) were excised and observed grossly. They were cut at 3-5mm and were processed by the use of an automatic tissue processor (Hestion-ATP7000 tissue processor-Germany) for dehydration, clearing, and impregnation. After embedding, sections were obtained at 3-5microns using digital rotary microtome (HestionERM 4000 Germany).

Photomicrography Mayer's haematoxylin and eosin stained sections were examined using the Swift(R) binocular microscope® (Olympus England) with an in-built lighting system at x10 and

40 magnifications. Histopathological scoring was reviewed by two or more pathologist at the Federal Medical Centre Owerri. The study lasted between January, 2020 and March, 2020

Photomicrography and statistical analysis

Olympus photomicroscope (Opticshot-2; Nikon, Tokyo, Japan) was used at x40 magnification. Data were presented as Means \pm S.E.M and significance were determined at $p < 0.05$ using one way analysis of variance (ANOVA) and differences between pairs of means within the four groups of rats (treated and untreated) were made by using the Student's test.

Results and analysis

Weight of Albino rats treated with oral administration of different doses *Daucuscarota* root extract and control for 28days

Table 1: Initial weight (g) and final weight (g) of albino rats before and after 28 days

Groups	Initial weight (g)	Final weight (g)
A 000	151.95 \pm 5.6	154.71 \pm 6.2
B Disprin only	150.27 \pm 6.1	145.47 \pm 6.2
C 50mg DC + Dispirin	166.38 \pm 4.3	170.63 \pm 5.8
D 150mg DC+Dispirin	168.45 \pm 5.8	178.45 \pm 7.1
E 200mg DC+ Dispirin	166.73 \pm 6.8	180.93 \pm 7.4

Table 2: The mean level of serum creatinine and urea in albino rats administered with different doses of *Daucuscarota* extract, control and dispirin

Groups	Creatinine (mg/dl)	Urea (mg/dl)
A 000	0.5± 0.2	28.91± 4.8
B Disprin only	0.97± 0.1*	42.21± 7.3*
C 50mg DC + Dispirin	0.68± 0.3	35.28± 6.2*
D 150mg DC+Dispirin	0.65± 0.1	32.08± 6.1*
E 200mg DC+ Dispirin	0.60± 0.3	30.13± 4.4*

Fig. 1 Photomicrograph of the kidney of the control (CN). H&E ×400. Intact renal corpuscles with normal appearing glomeruli (G) and tubules (T), including the PCT (P) and DCT (D), are seen in control, as well as intact Bowman space (black arrow) and epithelial lining of Bowman capsule (arrowhead).

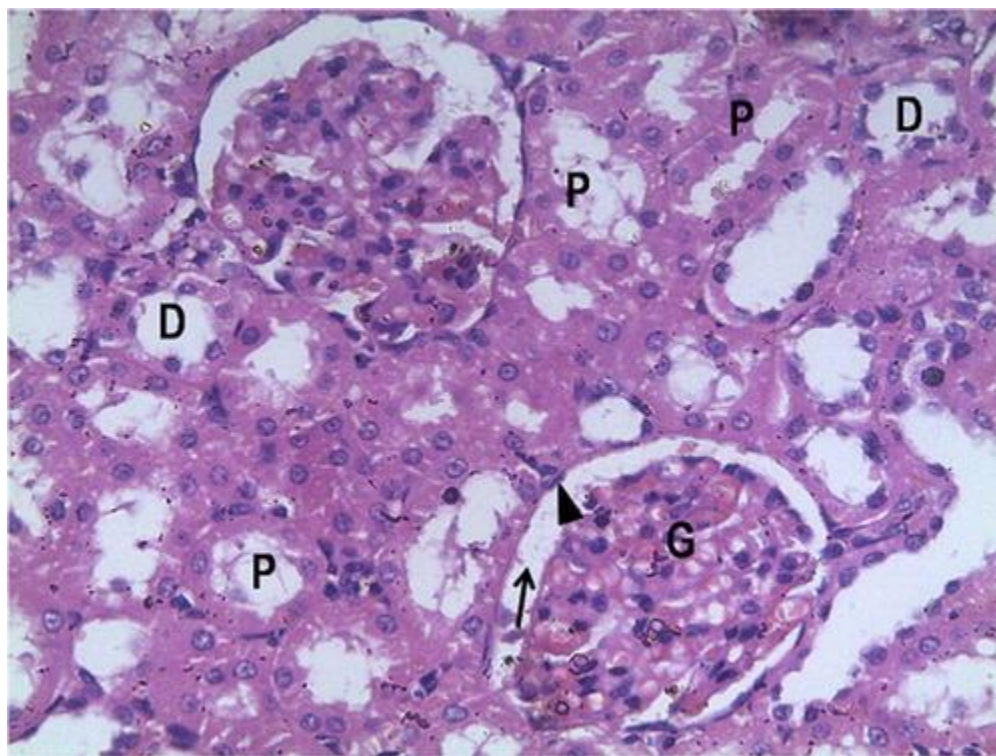


Fig. 2 Photomicrograph of the kidney of the toxic control (Dispirin only) (TX). H&E $\times 400$. Decreased cellularity in the glomeruli, loss of cellular constituents of tubules (double arrow), densely eosinophilic ('colloid') cast in the lumen of some tubules (dashed arrow) resulting in atrophy, loss of epithelia cells and severe cloudy swelling/inflammation of the distal convoluted tubules (yellow arrow) are observed in the toxic control group.

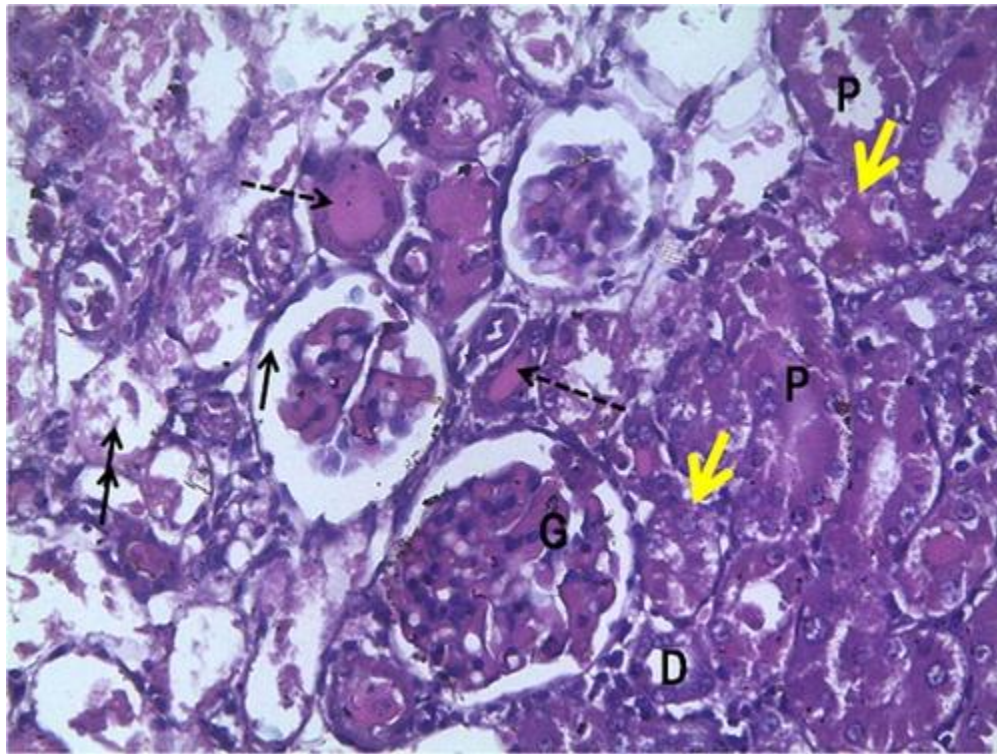
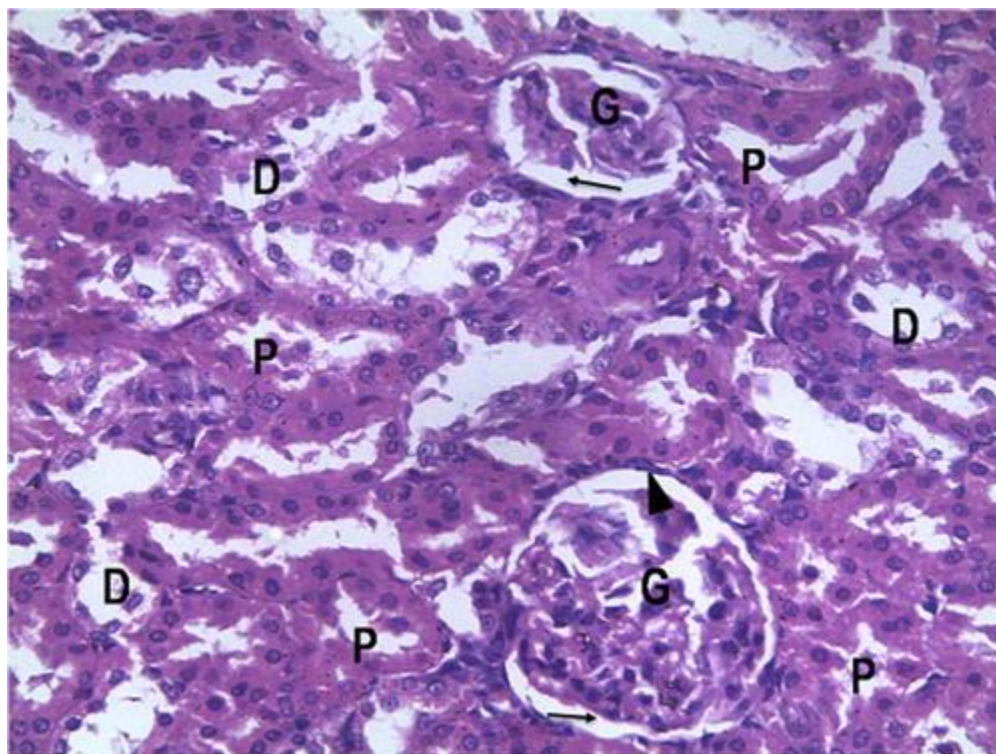


Fig. 3. Photomicrograph of the kidney treatment with 50 mg/kg/day of *Daucuscarota* extract. H&E $\times 400$. Glomeruli (G) and surrounding Bowman's space (black arrow) are mostly intact. There is slight loss of cellular constituents of tubules and no eosinophilic ('colloid') casts are observed in the lumen of tubules.



Ikem, A.P., Okolie, N. and Nnodim, J. (2022). Histomorphological Effects of DaucusCarota Extract on Dispirin Induced Kidney Damage in Albino Rats. *Madonna University Journal of Medicine and Health Sciences*.2(1):204-217

Fig. 4 Photomicrograph of the kidney treatment with 100 mg/kg/day of *Daucuscarota* extract. H&E ×400. Glomeruli (G) and surrounding Bowman's space (black arrow) are mostly intact. There is slight loss of cellular constituents of tubules and no eosinophilic ('colloid') casts are observed in the lumen of tubules.

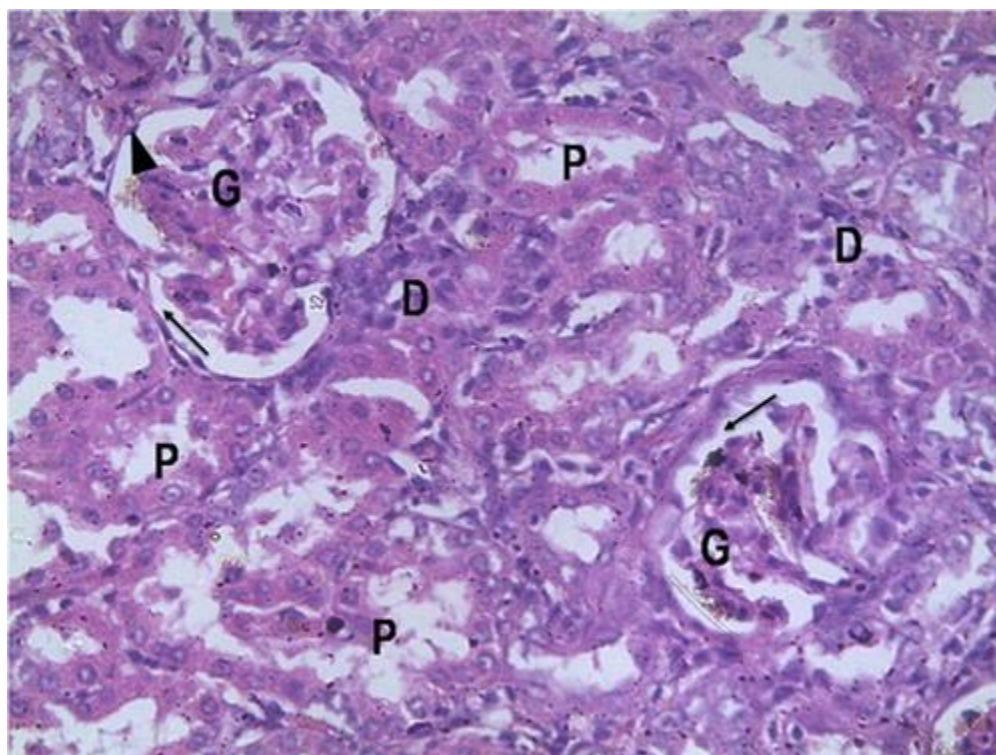
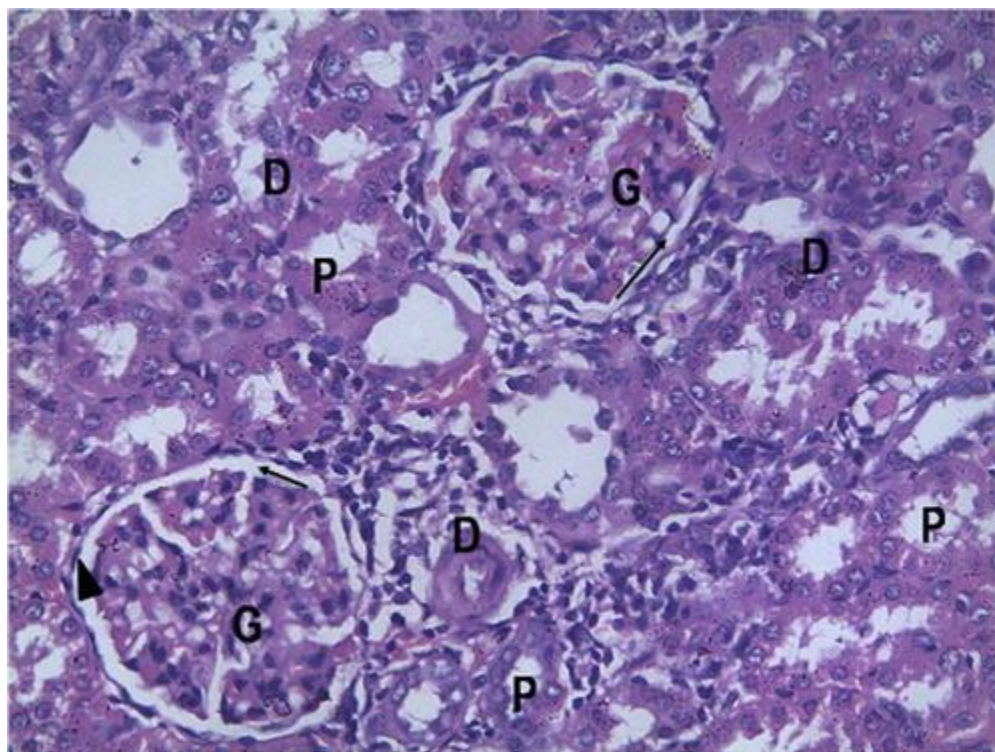


Fig. 5 Photomicrograph of the kidney treatment with 200 mg/kg/day of *Daucuscarota* extract. H&E ×400 (right). Glomeruli (G) and surrounding Bowman's space (black arrow) are mostly intact. There is slight loss of cellular constituents of tubules and no eosinophilic ('colloid') casts are observed in the lumen of tubules.

Ikem, A.P., Okolie, N. and Nnodim, J. (2022). Histomorphological Effects of *DaucusCarota* Extract on Dispirin Induced Kidney Damage in Albino Rats. *Madonna University Journal of Medicine and Health Sciences*.2(1):204-217



Discussion

Daucuscarota is used medicinally worldwide. The root and stem of the plant are used medicinally to treat different ailments. All parts of the plant have different ethno-medicinal uses for both man and animal alike. Medicinal plants are believed to be an important source of new chemical substances with potential therapeutic effects (El-Sayedel *et al.*, 2008). The kidney's functional integrity is to maintain total body homeostasis through its role in the excretion of metabolic wastes and in regulation of intracellular fluid volume, electrolyte composition, and acid-base balance. This therefore implies that any harmful effect on body metabolism could be suggestive of toxic insult to the kidney (Parlakpinar *et al.*, 2005)

In this study, administration of *Daucuscarota* extract in rats caused significant increase in body weight as was noted in the experimental groups treated with *Daucuscarota* extract. This may be Ikem, A.P., Okolie, N. and Nnodim, J. (2022). Histomorphological Effects of *DaucusCarota* Extract on Dispirin Induced Kidney Damage in Albino Rats. *Madonna University Journal of Medicine and Health Sciences*.2(1):204-217

as a result of the fact that *Daucuscarota* extract induced inhibition of the intestinal motility, together with increase in the number of villi of the intestine and larger goblets cells, which favor rapid absorption of nutrient from the gastro-intestinal tract. This is in agreement with the report of Gabrielle and Hans (2014) who reported that *Daucuscarota* extract administered at different doses caused a significant increase in the body weight. It could also be due to its hypoglycemic property attributed to flavonoids and other phytochemical constituents of *Daucuscarota* extract which promote food intake in albino rats. The extract also contains major mineral elements, e.g. calcium, chloride, manganese, magnesium, zinc and potassium, which might also play a contributory role in enhancing its hypoglycemic property (Rashid *et al.*, 2005)

The results from this study indicate that aqueous extract of *Daucuscarota* popularly has an increasing effects on the body weight of the experimental animals administered with dispirin. This significant increase in the body weights of the experimental animals was observed in a pattern suggesting the influence of the administered dosage (Wang *et al.*, 2010).

The plasma creatinine and urea concentrations of the group that was administered with dispirin only were significantly higher than that of the control rats. These observed changes are in accordance with the report of Baranski *et al.* (2012) who reported that administration of dispirin caused marked impairment in renal function. The elevated concentration of plasma urea observed may have resulted from the inability of the glomeruli to filter urea. A significant decrease toward normal plasma level of creatinine and urea that was observed in the groups that received different doses of *Daucuscarota* extract is an indication of tubular regeneration resulting from the release of reparative and prosurvival factors from the distal tubular cells. The marked decrease in plasma creatinine and urea in *Daucuscarota* extract treated groups is in conformity with report of other researchers. This is an indication of improved blood flow to the kidney as well as repair of kidney tissue damage caused by dispirin. Therefore, this further suggests that *Daucuscarota* root extract is not toxic to the histology of the kidney (Liu, 2012).

Ikem, A.P., Okolie, N. and Nnodim, J. (2022). Histomorphological Effects of *DaucursCarota* Extract on Dispirin Induced Kidney Damage in Albino Rats. *Madonna University Journal of Medicine and Health Sciences*.2(1):204-217

The histological observations of kidney sections from the groups that received dispirin only indicated some pathological states such as congestion of blood vessels, focal interstitial hemorrhage, and glomerular hemorrhages. This indeed is indication of renal tissue distortion suggestive of tissue damage in the group received dispirin only, whereas the histological appearance of the control group is consistent with normal histology. It can also be inferred that the activity of *Daucuscarota* extract on the kidney is dose dependent considering the increase in the restoration of distorted kidney tissue with increase in the extract administration (Devbhuti *et al.*, 2010)

Conclusion

This study demonstrated the nephron-restorative effect of *Daucuscarota* extract in dispirin induced nephrotoxicity in rats. The ameliorative effect of *Daucuscarota* extract is evident by a remarkable restoration of markers of renal function such as urea, and creatinine levels in dispirin treated rats.

References

Baranski, R; Maksylewicz-Kaul, A; Nothnagel, T; Cavagnaro, P F.; Simon, P W.; Grzebelus, D (2012). Genetic diversity of carrot (*Daucuscarota* L.) cultivars revealed by analysis of SSR loci. *Genetic Resources and Crop Evolution*. 59 (2): 163–170

Clark, D. L.; Wilson, M. V. (2003). Post-dispersal seed fates of four prairie species. *American Journal of Botany*. 90 (5): 730–5.

Coxon, D T.; Curtis, R.F; Price, K R.; Levett, G (1973). "Abnormal metabolites produced by *Daucuscarota* roots stored under conditions of stress". *Phytochemistry*. 12 (8): 1881–1885.

.

Crosby, D.G.; Aharonson, N. (1967). "The structure of carotatoxin, a natural toxicant from carrot". *Tetrahedron*. 23 (1): 465–472

Daniel E. B (2017). Michael A Miller (ed.). Hemlock Poisoning. *Medscape*. 45-50

Ikem, A.P., Okolie, N. and Nnodim, J. (2022). Histomorphological Effects of *DaucusCarota* Extract on Dispirin Induced Kidney Damage in Albino Rats. *Madonna University Journal of Medicine and Health Sciences*. 2(1):204-217

Devbhuti P, Sengupta C, Saha A (2010). Studies on amikacin induced lipid profile and peroxidation parameters and their control with ascorbic acid. *Int J of Curr Pharmaceut Res.* ;2:76–81

Diamond GL (2005). Risk assessment of nephrotoxic metals. In: Tarloff J, Lash L, editors. *The Toxicology of the Kidney*. London: CRC Press; 2005. pp. 1099–1132.

El-Sayedel SM, Abo-Salem OM, Abd-Ellah MF, Abd-AllaGM (2008). Hesperidin, an antioxidant flavonoid, prevents acrylonitrile-induced oxidative stress in rat brain. *J Biochem Mol Toxicol* ;22:268–73.48

Flora SJ (2011). Arsenic induced oxidative stress and its reversibility. *Free Radic Biol Med.* 51:257–281.

Gabrielle CJ, Hans W (2014). Carrot Seed for Contraception: A Review. *Australian Journal of Herbal Medicine.* 26: 10–17

Goulson, D., Kate M., Emma E., Susan A, Louise C, Kirsty J. P, Matthew C. T., and Andre S. G (2009):. “Functional Significance of the Dark Central Floret of *Daucus Carota* (Apiaceae) L.; Is It an Insect Mimic?” *Plant Species Biology* 24, 2 77–82.

Liu CM, Sun YZ, Sun JM, Ma JQ, Cheng C.(2012) Protective role of quercetin against lead-induced inflammatory response in rat kidney through the ROS-mediated MAPKS and NF- κ B pathway. *Biochim Biophys Acta.* 1820:1693–170

Mimura I, Tojo A, Uozaki H, Fujita T (2008). Erythro-phagocytosis by renal tubular cells. *Kidney Int.* 74:398.

Parlakpınar H, Sahna E, Acet A, Mizrak B, Polat A.(2005) Effect of caffeic acid phenethyl ester (CAPE) on myocardial ischemia-reperfusion induced apoptotic cell death. *Toxicol*;207:169–77.

Rashid F, Kaleem M, Sheema S, Bano B (2005). Comparative effect of olive oil and fish oil supplementation in combating gentamicin induced nephrotoxicity in rats. *Indian J Clin Biochem.* ;20:109–14.49

Wang L, Wang H, Hu M, Cao J, Chen D, Liu Z (2009) Oxidative stress and apoptotic changes in primary cultures of rat proximal tubular cells exposed to lead. *Arch Toxicol.* 83:417–427.

Wang L, Li J, Liu Z.(2010) Effects of lead and/or cadmium on the oxidative damage of rat kidney cortex mitochondria. *Biol Trace Elem Res.* 137:69–78.

Ikem, A.P., Okolie, N. and Nnodim, J. (2022). Histomorphological Effects of *Daucus Carota* Extract on Dispirin Induced Kidney Damage in Albino Rats. *Madonna University Journal of Medicine and Health Sciences.* 2(1):204-217

Wurtele, E. S.; Wang, H.; Durgerian, S.; Nikolau, B. J.; Ulrich, T. H. (1993). Characterization of a Gene That Is Expressed Early in Somatic Embryogenesis of *Daucuscarota*". *Plant Physiology*. 102 (1): 303–12.

Ikem, A.P., Okolie, N. and Nnodim, J. (2022). Histomorphological Effects of DaucursCarota Extract on Dispirin Induced Kidney Damage in Albino Rats. *Madonna University Journal of Medicine and Health Sciences*.2(1):204-217
